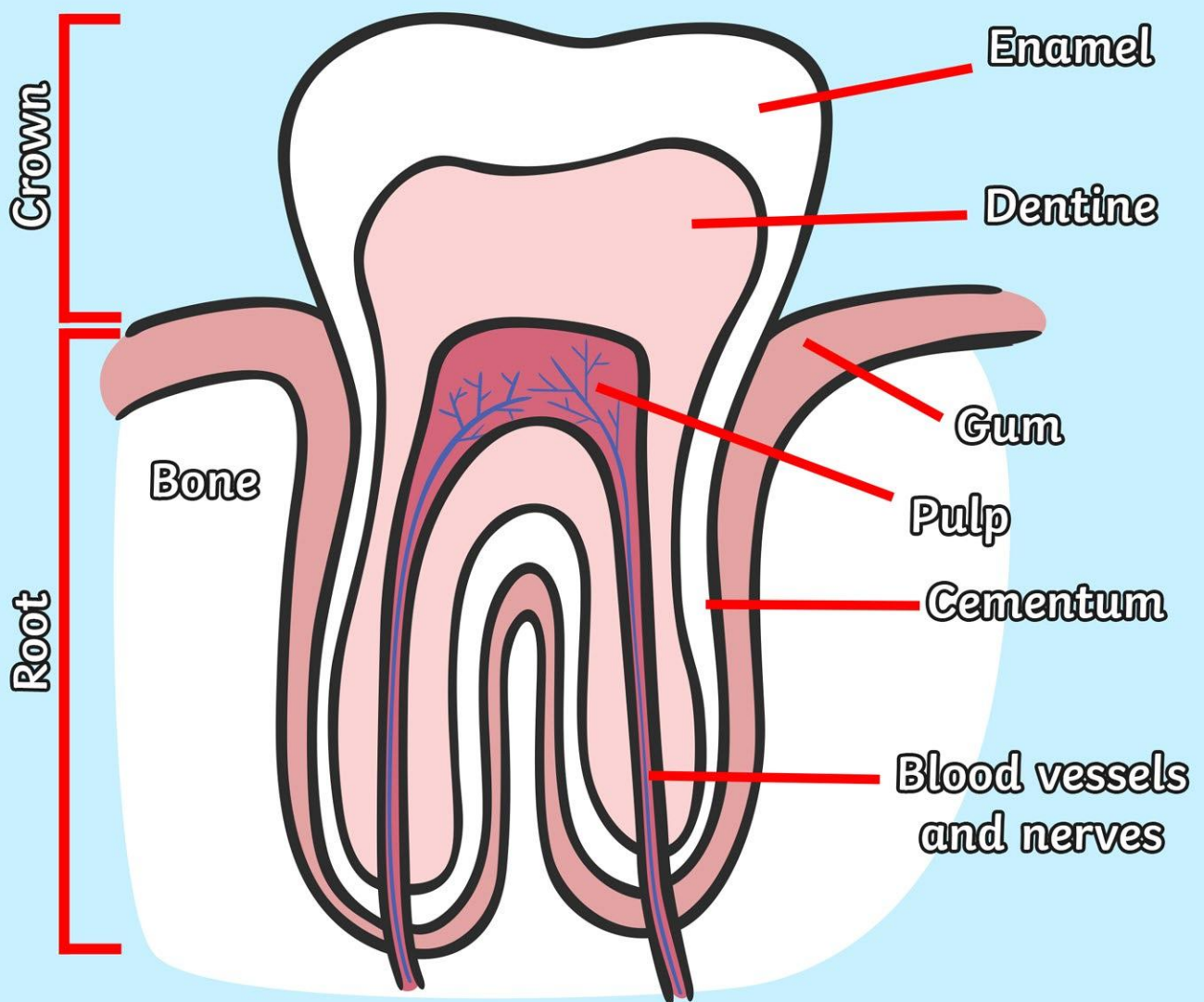


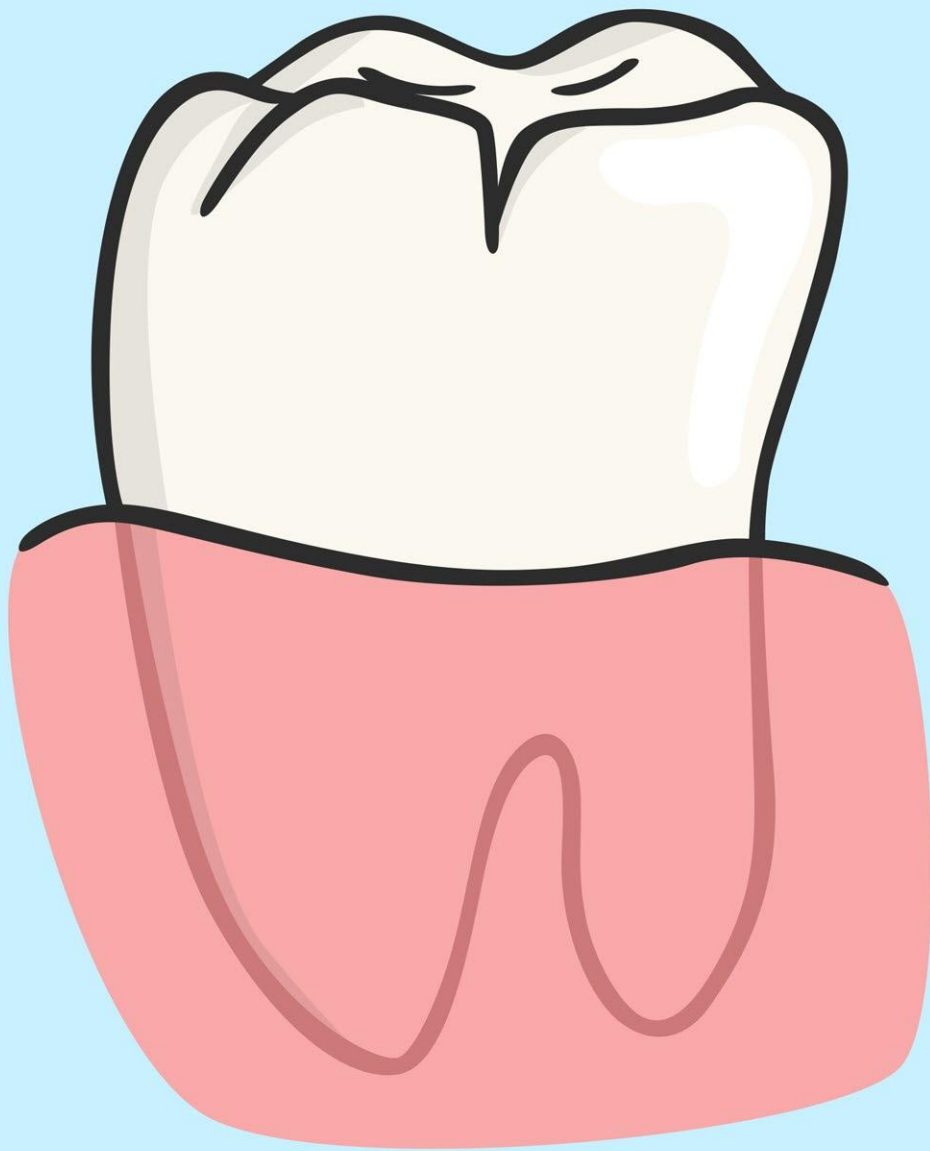
Diagram of a Tooth




Incisor



Molar



Canine



Premolar




Diagram of the Mouth

